

# Progressive Loss of Lymphatic Vessels in Skin of Patients with Systemic Sclerosis

MIRKO MANETTI, ANNA FRANCA MILIA, SERENA GUIDUCCI, ELOISA ROMANO,  
MARCO MATUCCI-CERINIC, and LIDIA IBBA-MANNESCHI

**ABSTRACT.** *Objective.* Systemic sclerosis (SSc) is a connective tissue disorder characterized by microvascular and fibrotic changes in the skin and internal organs. The role of blood vessel dysfunction in the pathogenesis of SSc has been extensively investigated, but few studies have addressed the involvement of the lymphatic vascular system. Our aim was to evaluate dermal lymphatic vessels in patients with SSc according to different phases of skin involvement.

*Methods.* Skin biopsies were obtained from the forearm of 25 SSc patients (10 early/15 late-stage disease) and 13 healthy controls. Skin sections were immunostained for podoplanin (D2-40), which is selectively expressed in lymphatic endothelial cells, and examined by confocal laser scanning microscopy. Lymphatic vessels were counted in the papillary and reticular dermis. Data were analyzed using Student's t test.

*Results.* The number of lymphatic vessels was significantly reduced in the papillary and reticular dermis of SSc patients compared with controls. In early SSc, lymphatic vessel counts were not different from controls in the papillary dermis, and showed a trend toward a reduction in the reticular dermis. In late SSc, a significant reduction in lymphatic vessels compared with controls was found in both the papillary and reticular dermis. The number of lymphatic vessels in the papillary dermis of late SSc was significantly lower than in early SSc.

*Conclusion.* In SSc, lymphatic microangiopathy is linked to the progression of skin involvement. The progressive disappearance of lymphatic vessels may have a critical pathogenetic role in the progression of SSc from an early edematous phase to overt fibrosis. (First Release Nov 15 2010; J Rheumatol 2011;38:297–301; doi:10.3899/jrheum.100767)

## Key Indexing Terms:

SYSTEMIC SCLEROSIS

SCLERODERMA

LYMPHATIC VESSELS

SKIN

The pathogenesis of systemic sclerosis (SSc, scleroderma) is heterogeneous, including vasculopathy and activation of fibroblasts and the cellular immune system, but microvascular damage remains the hallmark of the disease<sup>1,2,3</sup>. Raynaud's phenomenon and microcirculatory abnormalities are the earliest disease manifestations, and may precede the onset of fibrosis by months or years<sup>2,3</sup>. In the early phase,

endothelial cell activation and increased vascular permeability favor the formation of cutaneous edema and perivascular inflammatory infiltrates<sup>2,4</sup>. The severe disarray of the microcirculation is characterized by vascular modifications and a variable loss of capillaries<sup>4,5,6</sup>. With disease progression, proliferation of the intima leads to vessel narrowing and obliteration. The decreased blood flow causes chronic ischemia, lack of nutrients, and severe tissue hypoxia that often manifests clinically as digital ulcers or gangrene<sup>2,3,4</sup>.

In the pathogenesis of SSc the role of blood vessel dysfunction has been extensively investigated, but only a few studies have addressed the involvement of the lymphatic vascular system<sup>7,8,9</sup>. Lymphatic vessels differ from blood vessels in several ways. Lymphatic capillaries are thin-walled and blind-ended endothelial tubes that, unlike typical blood capillaries, lack pericytes and a continuous basal lamina and present large interendothelial valve-like openings<sup>10,11,12</sup>. Lymphatic endothelial cells contain anchoring filaments that connect them to the extracellular matrix and contribute to the maintenance of vessel patency during increased tissue pressure and inflammation<sup>11,12</sup>. Due to their greater permeability, lymphatic capillaries within most organs are more effective than blood capillaries in draining protein-rich fluid with clearance of macromolecules from

From the Department of Anatomy, Histology and Forensic Medicine, University of Florence, Florence; and Department of Biomedicine, Division of Rheumatology, AOUC, and Excellence Centre for Research, Transfer and High Education DENOthe, University of Florence, Florence, Italy.

Supported by the University of Florence (to L. Ibba-Manneschi and M. Matucci-Cerinic) and the Associazione per lo studio della Sclerosi Sistemica e delle Malattie Fibrosanti (ASSMaF onlus).

M. Manetti, PhD, Department of Anatomy, Histology and Forensic Medicine, Department of Biomedicine, Division of Rheumatology, AOUC, and Excellence Centre for Research, Transfer and High Education DENOthe; A.F. Milia, PhD; S. Guiducci, MD; E. Romano, PhD; M. Matucci-Cerinic, MD, PhD, Department of Biomedicine, Division of Rheumatology, AOUC, and Excellence Centre for Research, Transfer and High Education DENOthe; L. Ibba-Manneschi, MD, Department of Anatomy, Histology and Forensic Medicine, University of Florence.

Address correspondence to Prof. L. Ibba-Manneschi, Department of Anatomy, Histology and Forensic Medicine, University of Florence, Viale G.B. Morgagni 85, I-50134, Florence, Italy. E-mail: [ibba@unifi.it](mailto:ibba@unifi.it)

Accepted for publication September 21, 2010.

the interstitium<sup>12,13</sup>. In lymphatic vessel insufficiency, macromolecules accumulate and increase tissue oncotic and hydrostatic pressure, resulting in impaired tissue perfusion and dystrophic changes<sup>12,13</sup>. Lymphatic vessels also play major roles in the immune response through lymphocyte recirculation and trafficking of antigen-presenting cells, dendritic cells, and Langerhans cells from peripheral tissues to lymph nodes<sup>12</sup>.

Recently, it was shown that the number of lymphatic vessels is significantly reduced in the skin of patients with SSc and correlates inversely with the number of fingertip ulcers<sup>8,9</sup>. However, the pathogenetic mechanisms and timing of disappearance of lymphatic vessels in SSc remain poorly understood. The aim of our study was to evaluate dermal lymphatic vessels in a large series of skin biopsies from patients with SSc according to different stages of skin involvement.

## MATERIALS AND METHODS

**Patients, controls, and skin biopsies.** Full-thickness skin biopsies were obtained from the clinically involved skin of one-third of the distal forearm of 25 patients with SSc (23 women, 2 men; mean age  $44 \pm \text{SD } 15$  yrs) recruited from the Division of Rheumatology, Department of Biomedicine, University of Florence. All patients fulfilled the criteria for SSc as suggested by LeRoy and Medsger<sup>14</sup>. Patients were classified as having limited cutaneous SSc (lcSSc;  $n = 11$ ) or diffuse cutaneous SSc (dcSSc;  $n = 14$ ) according to the criteria proposed by LeRoy, *et al*<sup>15</sup>. Disease duration was calculated since the first non-Raynaud's symptom of SSc. Patients were further classified as being in the early ( $n = 10$ , 4 lcSSc, 6 dcSSc) or late ( $n = 15$ , 7 lcSSc, 8 dcSSc) phase of SSc according to disease duration (early lcSSc, disease duration  $< 5$  yrs; early dcSSc, disease duration  $< 3$  yrs) and to the clinical and pathological stage of skin involvement<sup>16</sup>. We considered clinically involved skin for values of skin thickness  $\geq 2$ , according to the modified Rodnan skin thickness score<sup>17,18</sup>. In SSc, the skin score evaluates the thickness of skin as assessed by clinical palpation of 17 body areas on a scale of 0–3 (0 = normal, 1 = mild thickening, 2 = moderate thickening, 3 = severe thickening), and from the sum of the scores from all body areas, with a maximum possible total score of 51<sup>18</sup>. All patients with SSc underwent a 15-day treatment washout before skin biopsy was performed. During this period only proton-pump inhibitors were allowed. Patients who could not undergo washout due to severe organ complications were not enrolled in the study. Skin samples from the same forearm region of 13 age- and sex-matched healthy donors were used as controls (12 women, 1 man; mean age  $42 \pm \text{SD } 16$  yrs). All patients and controls signed an informed consent form, and the study complied with the principles of the Declaration of Helsinki and was approved by the local ethics committee.

**Histopathology.** Each skin biopsy was fixed in 10% buffered formalin, dehydrated in a graded ethanol series and xylol, and embedded in paraffin. Paraffin sections ( $5 \mu\text{m}$  thick) were deparaffinized and either stained with hematoxylin and eosin (H&E) for routine histology or processed for immunohistochemistry. H&E-stained tissue sections were carefully examined for histopathological changes by 2 experienced observers blinded to sample classification.

**Immunohistochemistry and confocal laser scanning microscopy.** For antigen retrieval, skin sections ( $5 \mu\text{m}$  thick) were boiled for 10 min in citrate buffer (10 mM, pH 6.0) followed by cooling of the slides for 20 min at room temperature in the same buffer. The sections were then washed 3 times in phosphate buffered saline (PBS) and blocked for 1 h at room temperature with 1% bovine serum albumin (BSA) in PBS (BSA/PBS). For specific detection of lymphatic vessels, we used the recently discovered mouse monoclonal antibody D2-40 (Dako, Hamburg, Germany) that reacts

with a fixation-resistant epitope in podoplanin (originally identified as T1 $\alpha$ /E11 protein), a transmembrane sialoglycoprotein expressed at high levels in lymphatic endothelial cells but not in blood vascular endothelial cells<sup>19</sup>. The slides were incubated with D2-40 diluted 1:50 in BSA/PBS overnight at 4°C. After extensive washing in PBS, slides were incubated with Rhodamine Red-X-conjugated goat anti-mouse IgG (1:200 dilution; Molecular Probes, Eugene, OR, USA) as secondary antibodies for 45 min at room temperature in the dark. Irrelevant isotype- and concentration-matched IgG (Sigma, St. Louis, MO, USA) were used as negative controls. Cross-reactivity of secondary antibodies was tested in control experiments in which the primary antibody D2-40 was omitted. Skin sections were examined with a Leica TCS SP5 confocal laser scanning microscope (Leica Microsystems, Mannheim, Germany) equipped with a Leica PlanApo  $\times 63/1.40$  NA oil immersion objective and a HeNe/Argon laser source for fluorescence measurements and differential interference contrast optics for transmission images. Series of optical sections ( $1024 \times 1024$  pixels) at intervals of  $0.4 \mu\text{m}$  were obtained and superimposed to create a single composite image. Images were obtained at 20 $\times$  and 63 $\times$  original magnification and analyzed by ImageJ software (National Institutes of Health, Bethesda, MD, USA).

**Determination of numbers of lymphatic vessels.** D2-40-immunopositive lymphatic vessels were counted in 15 randomly chosen microscopic high-power fields (hpf; 63 $\times$  original magnification) of the papillary dermis and 15 hpf of the reticular dermis per sample by 2 independent investigators blinded to skin biopsy classification. The mean of the 2 different observations for each sample was used for analysis.

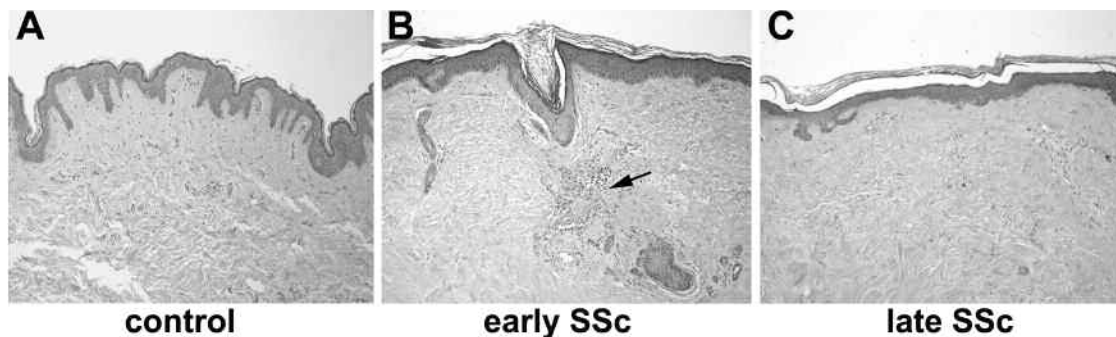
**Statistical analysis.** Data are presented as the mean  $\pm$  SD. Student's *t* test for independent data was used to test the probability of significant differences between group mean values. Values of  $p < 0.05$  were considered statistically significant.

## RESULTS

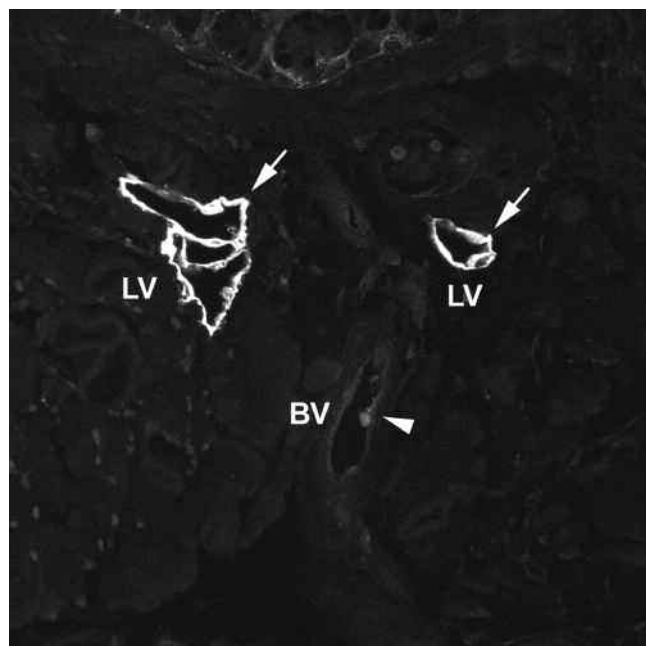
In the early phase of SSc, the main histopathological features were represented by a relevant perivascular inflammatory infiltrate, as well as edema around the microvessels and a variable extent of collagen accumulation in the papillary and reticular dermis (Figure 1). In late-phase SSc, flattening of papillae, a marked reduction in microvessel density, and severe dermal sclerotic changes characterized by tightly packed and irregularly distributed collagen bundles were evident (Figure 1).

Lymphatic vessels were consistently and strongly immunostained by the monoclonal antibody D2-40 in the papillary and reticular dermis of all skin sections from patients with SSc and healthy controls (Figures 2 and 3A). Its immunoreactivity specifically delineated flattened channels or open spaces lined by a single layer of endothelial cells whose lumen was sometimes filled with lymphocytes. Blood vessels were consistently negative for D2-40 (Figure 2).

We first compared lymphatic vessel counts in the whole SSc group with those in the healthy control group. The number of D2-40-immunopositive lymphatic vessels was significantly reduced in the SSc papillary dermis ( $1.03 \pm 0.52/\text{hpf}$  vs  $1.64 \pm 0.44/\text{hpf}$  in controls;  $p < 0.001$ ) and reticular dermis ( $1.08 \pm 0.35/\text{hpf}$  vs  $1.79 \pm 0.66/\text{hpf}$  in controls;  $p < 0.001$ ) compared to healthy individuals (Figure 3B). No significant differences in lymphatic vessel counts were observed between lcSSc and dcSSc patients (data not shown).



**Figure 1.** Skin histopathology in systemic sclerosis (SSc). (A) Control skin. (B) In early SSc, there is dermal inflammation characterized by perivascular mononuclear cell infiltrates composed of monocytes and lymphocytes (arrow), with edema around the microvessels and a variable extent of fibrosis in the papillary and reticular dermis. (C) In late SSc, prominent collagen accumulation leads to dermal thickening and deposition of dense and closely packed collagen bundles throughout the dermis, with loss of the microvasculature and dermal structures, and flattening of papillae. All sections stained with H&E; original magnification  $\times 10$ .



**Figure 2.** Immunohistochemical identification of lymphatic vessels in skin biopsies. For specific detection of lymphatic vessels, we used the mouse monoclonal antibody D2-40 that reacts with a fixation-resistant epitope in podoplanin, a transmembrane sialoglycoprotein expressed at high levels in lymphatic endothelial cells but not in blood vascular endothelial cells. Lymphatic vessels (LV) are strongly immunostained by D2-40 (arrows), while blood vessels (BV) are negative for D2-40 (arrowhead). Original magnification  $\times 63$ .

We next examined whether there were differences in lymphatic vessel numbers between patients in early and late phases of SSc. In early SSc, the number of lymphatic vessels was not different from controls in the papillary dermis ( $1.42 \pm 0.36/\text{hpf}$  vs  $1.64 \pm 0.44/\text{hpf}$ , respectively), while a reduction was observed in the reticular dermis ( $1.21 \pm 0.33/\text{hpf}$  vs  $1.79 \pm 0.66/\text{hpf}$ ) ( $p = 0.05$ ; Figure 3C). In late SSc, a significant reduction in lymphatic vessel counts was found both in the papillary dermis ( $0.72 \pm 0.42/\text{hpf}$  vs  $1.64$

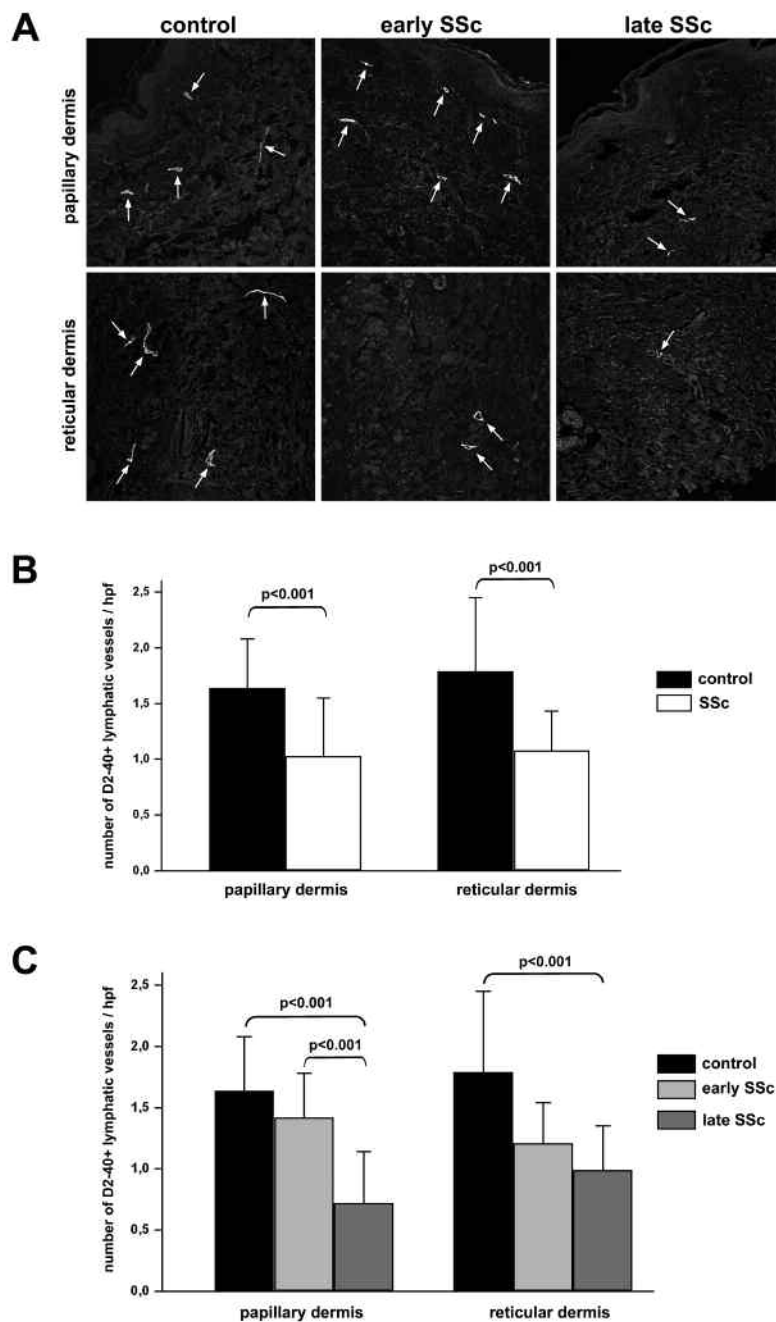
$\pm 0.44/\text{hpf}$ ;  $p < 0.001$ ) and in the reticular dermis ( $0.99 \pm 0.36/\text{hpf}$  vs  $1.79 \pm 0.66/\text{hpf}$ ;  $p < 0.001$ ) compared to healthy individuals (Figure 3C). Moreover, in the papillary dermis of late SSc the number of lymphatic vessels was significantly lower, compared with early SSc ( $p < 0.001$ ; Figure 3C).

## DISCUSSION

We confirmed the reduction in number of lymphatic vessels in the skin of patients with SSc<sup>8,9</sup>, and we show for the first time that the loss of lymphatics is linked to the progression of skin involvement. The number of lymphatic vessels was similar in patients with early SSc and healthy controls in the papillary dermis, and a trend toward a reduction was observed in the reticular dermis. However, we found a severe reduction of lymphatics in both the papillary and reticular dermis of late SSc. The progression of lymphatic loss is corroborated by the evidence of fewer lymphatic vessels in the papillary dermis of late SSc compared to early SSc samples. Indeed, our data also indicate that the loss of cutaneous lymphatic vessels starts early in the reticular dermis and extends afterwards to the papillary dermis.

Our immunohistochemical results are in agreement with those of Leu, *et al*<sup>7</sup>; using fluorescence microlymphography, they showed in clinically affected SSc skin a lymphatic microangiopathy similar to that commonly found in lymphedema and chronic venous insufficiency. They also found a correlation between disease duration and impairment of the lymphatic vascular network<sup>7</sup>.

Lymphatic vessel dysfunction and disappearance may have a critical pathophysiological role in the course of SSc. The capacity to drain protein-containing fluid and cells from the interstitium is essential for maintaining fluid homeostasis. The lymphatic vasculature drives this process by taking up fluid and macromolecules from the tissues into blind-ended small lymphatic capillaries and transporting lymph fluid via a network of increasingly larger vessels to the venous system<sup>12</sup>. Unlike blood vessels, which are struc-



**Figure 3.** Evaluation of podoplanin (D2-40)-immunopositive lymphatic vessels in the skin of patients with SSc and healthy controls. (A) Papillary and reticular dermis of skin sections from controls, patients with early SSc, and patients with late SSc immunostained with the monoclonal antibody D2-40. Podoplanin-positive lymphatic vessels are indicated by arrows. Original magnification  $\times 20$ . (B, C) Results of counts of D2-40-positive lymphatic vessels in skin of controls and patients with SSc. Bars show mean  $\pm$  SD values of lymphatic vessel number/high-power field. p values calculated by Student t test.

turally more robust to cope with the high pressure generated by the heart, the lymphatic vasculature is a low pressure system. An increase in interstitial fluid pressure causes overlapping lymphatic interendothelial cell junctions to open, permitting passage of fluid and particles into the vessel. As fluid enters the lumen, pressure differences across the vessel

wall decrease and the junctions begin to close, preventing retrograde flow back into the interstitium<sup>20</sup>. Impairment of lymphatic transport capacity due to abnormal vessel development or obliteration and loss of the lymphatic capillaries causes stagnation of macromolecules and fluid in the interstitium, resulting in lymphedema<sup>12,13</sup>. The protein-rich



interstitial fluid initiates a persistent inflammatory response, leading to impaired immune responses, tissue dystrophic changes, and fibrosis<sup>12</sup>. These characteristics are found in SSc, where an inverse correlation between lymphatic vessel counts and fingertip ulcers has been reported<sup>9</sup>.

In SSc, different pathogenetic mechanisms could be responsible for the loss of cutaneous lymphatic vessels. Similarly to what has been hypothesized for impairment of the blood microcirculation, an uncontrolled expression of lymphangiogenic growth factors and receptors, altered numbers and functional defects of circulating lymphatic endothelial progenitor cells, and antiendothelial cell antibodies might have a role in the lymphatic microangiopathy of SSc<sup>4</sup>. In SSc, serum levels of the lymphangiogenic vascular endothelial growth factor-C (VEGF-C) and dermal expression of VEGF-D and its receptor VEGFR-3 (Flt-4) have been reported to be increased<sup>21,22,23</sup>. However, no data are available on other molecules that could be potentially involved in lymphatic endothelial cell activation/damage, or on lymphatic endothelial precursors. Lymphatic capillaries could be more sensitive to damage than their blood circulation counterpart because of the more fragile structure, with a single lining of endothelial cells, an incomplete basement membrane, and lack of supporting pericytes<sup>10,11,12</sup>.

The complex relationship between lymphangiopathy and fibrosis deserves further investigation. Indeed, lymphangiopathy in SSc could both precede the fibrotic process, as in chronic lymphedema<sup>12</sup>, and follow it. Our findings show that cutaneous lymphatic vessel involvement starts in the early phase of SSc, and progresses to a significant loss of lymphatic capillaries in the late disease phase. Lymphatic capillary function is critically dependent on its connections with the extracellular matrix. Lymphatic endothelial cells are attached to interstitial collagen by anchoring filaments, composed of elastic fibers, that preserve functionality of the lymphatics when interstitial pressure rises by preventing vessel collapse<sup>11,24</sup>. In SSc, the altered composition and organization of extracellular matrix could also have a role in lymphatic vessel dysfunction.

In summary, lymphatic capillaries are affected in the skin of early and late-stage SSc to different extents. The progressive disappearance of lymphatic vessels may have a critical pathogenetic role in the progression of SSc from an early edematous phase to overt fibrosis.

## REFERENCES

1. Varga J, Abraham D. Systemic sclerosis: a prototypic multisystem fibrotic disorder. *J Clin Invest* 2007;117:557-67.
2. LeRoy EC. Systemic sclerosis: a vascular perspective. *Rheum Dis Clin North Am* 1996;22:675-94.
3. Guiducci S, Giacomelli R, Matucci-Cerinic M. Vascular complications of scleroderma. *Autoimmun Rev* 2007;6:520-3.
4. Manetti M, Guiducci S, Ibba-Manneschi L, Matucci-Cerinic M. Mechanisms in the loss of capillaries in systemic sclerosis: angiogenesis versus vasculogenesis. *J Cell Mol Med* 2010;14:1241-54.
5. Cutolo M, Sulli A, Pizzorni C, Accardo S. Nailfold videocapillaroscopy assessment of microvascular damage in systemic sclerosis. *J Rheumatol* 2000;27:155-60.
6. Sulli A, Secchi ME, Pizzorni C, Cutolo M. Scoring the nailfold microvascular changes during the capillaroscopic analysis in systemic sclerosis patients. *Ann Rheum Dis* 2008;67:885-7.
7. Leu AJ, Gretener SB, Enderlin S, Brühlmann P, Michel BA, Kowal-Bielecka O, et al. Lymphatic microangiopathy of the skin in systemic sclerosis. *Rheumatology* 1999;38:221-7.
8. Rossi A, Sozio F, Sestini P, Renzoni EA, Khan K, Denton CP, et al. Lymphatic and blood vessels in scleroderma skin, a morphometric analysis. *Hum Pathol* 2010;41:366-74.
9. Akhmetshina A, Beer J, Zwerina K, Englbrecht M, Palumbo K, Dees C, et al. Decreased lymphatic vessel counts in patients with systemic sclerosis: association with fingertip ulcers. *Arthritis Rheum* 2010;62:1513-22.
10. Casley-Smith JR. The fine structure and functioning of tissue channels and lymphatics. *Lymphology* 1980;12:177-83.
11. Leak LV. Electron microscopic observations on lymphatic capillaries and the structural components of the connective tissue-lymph interface. *Microvasc Res* 1970;2:361-91.
12. Tammela T, Alitalo K. Lymphangiogenesis: molecular mechanisms and future promise. *Cell* 2010;140:460-76.
13. Mallon EC, Ryan TJ. Lymphedema and wound healing. *Clin Dermatol* 1994;12:89-93.
14. LeRoy EC, Medsger TA Jr. Criteria for the classification of early systemic sclerosis. *J Rheumatol* 2001;28:1573-6.
15. LeRoy EC, Black C, Fleischmajer R, Jablonska S, Krieg T, Medsger TA Jr, et al. Scleroderma (systemic sclerosis): classification, subsets and pathogenesis. *J Rheumatol* 1988;15:202-5.
16. Clements PJ, Medsger TA Jr. Organ involvement: skin. In: Clements PJ, Furst DE, editors. *Systemic sclerosis*. Baltimore: Williams & Wilkins; 1996:389-407.
17. Clements PJ, Furst DE. *Systemic sclerosis*. 3rd ed. Baltimore: Williams & Wilkins; 2003.
18. Clements P, Lachenbruch P, Siebold J, White B, Weiner S, Martin R, et al. Inter and intraobserver variability of total skin thickness score (modified Rodnan TSS) in systemic sclerosis. *J Rheumatol* 1995;22:1281-5.
19. Kahn HJ, Bailey D, Marks A. Monoclonal antibody D2-40, a new marker of lymphatic endothelium, reacts with Kaposi's sarcoma and a subset of angiosarcomas. *Mod Pathol* 2002;15:434-40.
20. Schmid-Schönbein GW. Microlymphatics and lymph flow. *Physiol Rev* 1990;70:987-1028.
21. Chitale S, Al-Mowallad AF, Wang Q, Kumar S, Herrick A. High circulating levels of VEGF-C suggest abnormal lymphangiogenesis in systemic sclerosis. *Rheumatology* 2008;47:1727-8.
22. Mackiewicz Z, Sukura A, Povilenaite D, Ceponis A, Virtanen I, Hukkanen M, et al. Increased but imbalanced expression of VEGF and its receptors has no positive effect on angiogenesis in systemic sclerosis skin. *Clin Exp Rheumatol* 2002;20:641-6.
23. Honda N, Jinnin M, Kajihara I, Makino T, Fukushima S, Ihn H. Impaired lymphangiogenesis due to excess vascular endothelial growth factor-D/Flt-4 signalling in the skin of patients with systemic sclerosis. *Br J Dermatol* 2010;163:776-80.
24. Gerli R, Ibba L, Fruscelli C. A fibrillar elastic apparatus around human lymph capillaries. *Anat Embryol* 1990;181:281-6.