

# Implantable Cardioverter Defibrillator Prevents Sudden Cardiac Death in Systemic Sclerosis

PASQUALE BERNARDO, MARIA LETIZIA CONFORTI, SILVIA BELLANDO-RANDONE, PAOLO PIERAGNOLI, JELENA BLAGOJEVIC, OLGA KALOUDI, SERENA GUIDUCCI, FRANCESCO PORTA, LUIGI PADELETTI, GIAN FRANCO GENSINI, and MARCO MATUCCI-CERINIC

**ABSTRACT.** *Objective.* Cardiac involvement means a poor prognosis in systemic sclerosis (SSc). Conduction defects and arrhythmias are frequent in patients with SSc, and may result in sudden cardiac death. We tested whether electrophysiologic studies and implantation of cardioverter defibrillators are recommended when ventricular arrhythmias are present.

*Method.* A cardioverter defibrillator was implanted in 10 patients with SSc who had heart involvement.

*Result.* After 36 months, analysis of the device showed several episodes of ventricular tachycardia in 3 patients, which were promptly reverted by electrical shock delivery.

*Conclusion.* In patients with SSc who are affected by ventricular arrhythmias, the implantation of a cardioverter defibrillator may prevent sudden cardiac death. (J Rheumatol First Release June 1 2011; doi:10.3899/jrheum.100480)

## Key Indexing Terms:

SUDDEN CARDIAC DEATH

IMPLANTABLE CARIOVERTER DEFIBRILLATOR

VENTRICULAR TACHYARRHYTHMIAS

SYSTEMIC SCLEROSIS

Systemic sclerosis (SSc) is a remarkably heterogeneous disease<sup>1</sup> in which all organs may be involved to different degrees and progression of fibrosis<sup>2</sup>. Heart involvement is sometimes unnoticed and is frequently detected at postmortem examination<sup>2,3</sup>. Arrhythmias may be the first manifestation of heart involvement and are commonly detected during ambulatory monitoring<sup>4</sup>. SSc carries the threat of sudden cardiac death (SCD), especially in diffuse cutaneous SSc (dcSSc)<sup>5</sup>, reported in 21% to 54% of patients with SSc. It is likely caused by malignant ventricular tachycardia (VT)<sup>6</sup>. Overall, heart involvement is more frequent and severe in dcSSc, even though it is also present in limited cutaneous SSc (lcSSc). However, in an epidemiologic study, no significant difference in the onset of heart symptoms was detected between dcSSc and lcSSc<sup>7</sup>. Supraventricular and ventricular ectopy have been demonstrated in 67% of patients with SSc, while unsustained VT was present in 7%–13% of unselected patients with SSc<sup>3</sup>.

It has been shown that ventricular arrhythmias are significantly associated with increased mortality in SSc<sup>3</sup>, independently from visceral involvement or disease severity<sup>8</sup>. Moreover, VT occurs almost exclusively within the first few years of the onset of SSc<sup>8</sup>. Clinical factors such as age and systemic extent of SSc correlate with cardiac rhythm disturbances observed by ambulatory electrocardiography (ECG)<sup>8</sup>. However, conflicting data have emerged on the predictive value of lung disease for ventricular tachyarrhythmias. The duration of the disease, the extent of skin involvement, and the presence of serum antinuclear antibody did not predict ventricular arrhythmias<sup>9</sup>.

There is no evidence that drug therapy may decrease SCD mortality in patients with SSc. In one SSc case, an implantable cardioverter defibrillator (ICD) prevented SCD<sup>10</sup>. We report on a series of patients with SSc in whom the ICD has contributed to prevention of SCD.

## MATERIALS AND METHODS

Ten patients with SSc were observed (6 women and 4 men, mean age 48.6 ± 15.4 yrs, mean disease duration 2.5 ± 4.6 yrs). They had ventricular arrhythmias on 24-h Holter monitoring and were referred to the Department of Rheumatology of the University of Florence from 2007 to 2009.

Patients were classified as lcSSc (1 patient) or dcSSc (9 patients) and assessed according to international consensus criteria<sup>11</sup>. Antinuclear antibodies, antitopoisomerase I, and anticentromere antibodies were determined<sup>12</sup>.

Concomitant treatment included antiarrhythmic drugs (amiodarone, carvedilol, calcium-channel blockers), cyclophosphamide, and vasodilators. All patients underwent ECG, Holter ECG, Doppler echocardiography and tissue Doppler imaging, pulmonary function tests, lung high-resolution computed tomography (HRCT), measurement of plasma renin activity, and 24-h urine collection for protein excretion and creatinine clearance (Table 1).

All patients underwent myocardial scintigraphy and were examined by Tc-99 single-photon emission CT using a Millennium<sup>TM</sup> gamma camera (GE Healthcare, Waukesha, WI, USA) at rest and after dipyridamole stress. In 4

From the Department of Critical Care Medicine and Surgery, and the Department of Biomedicine, Division of Rheumatology AOUC, Denothe Centre, University of Florence, Florence, Italy.

P. Bernardo, MD, Department of Critical Care Medicine and Surgery; M.L. Conforti, MD; S. Bellando-Randone, MD, Department of Biomedicine, Division of Rheumatology AOUC, Denothe Centre; P. Pieragnoli, MD, Department of Critical Care Medicine and Surgery; J. Blagojevic, MD; O. Kaloudi, MD; S. Guiducci, MD, PhD; F. Porta, MD, Department of Biomedicine, Division of Rheumatology AOUC, Denothe Centre; L. Padeletti, MD; G.F. Gensini, MD, Department of Critical Care Medicine and Surgery; M. Matucci-Cerinic, MD, PhD, Department of Biomedicine, Division of Rheumatology AOUC, Denothe Centre, University of Florence.

Address correspondence to Dr. M. Matucci-Cerinic, Department of Biomedicine, Division of Rheumatology AOUC, Villa Monna Tessa, V. le Pieraccini 18, 50139 Florence, Italy. E-mail: cerinic@unifi.it  
Accepted for publication February 9, 2011.

Personal non-commercial use only. The Journal of Rheumatology Copyright © 2011. All rights reserved.

Table 1. Drug treatment and instrumental data of patients with systemic sclerosis (SSc).

Patient	Treatment	sPAP, mm Hg	Creatinine Clearance, ml/min	FVC/DLCO, (%)	TDI/EA	Ejection Fraction, %
1	Amiodarone (withdrawn because of hypothyroidism)	30	138	77/35	0.6	56
2	Amiodarone (withdrawn because of retinal deposits), calcium-channel blockers	30	76.2	98/64	1.3	56
3	Amiodarone	50	80	38/35	NA	50
4	Amiodarone, flecainide	25	87	110/130	NA	55
5	Amiodarone	35	70	81/67	< 1	40
6	Carvedilol	30	48	124/59	Close to normal	29
7	No drug treatment	25	50.28	76/72	< 1	NA
8	Amiodarone	20	82	88/68	> 1	55
9	Amiodarone	35	60	86/38	< 1	64
10	Clopidogrel, diltiazem	30	85	60/29	< 1	54

sPAP: systemic pulmonary arterial pressure; FVC: forced vital capacity; DLCO: diffusion lung capacity for carbon monoxide; TDI: tissue Doppler imaging; E/A ratio: (E) peak velocity of the early inflow phase, (A) peak velocity of the atrial inflow phase; NA: not applicable.

patients with abnormal perfusion, coronarography was performed, and one patient, with monocoronary disease, was treated with percutaneous transluminal coronary angioplasty and stenting.

Patients' informed consent was obtained before implantation. All patients were implanted with a third-generation ICD device (Guidant Corp., Indianapolis, IN, USA, and St. Jude Medical, model Epic DR, St. Paul, MN, USA) programmed to abort VT faster than 180 c/min. Before implantation of the ICD, 9 of the 10 patients were treated with antiarrhythmic drugs. In 2 patients, amiodarone was stopped because of retinal deposition and thyroid dysfunction. No patients were taking aspirin, and all were nonsmokers. Patients were followed up at 3, 6, 12, 24, and 36 months through analysis of the ICD recorder.

The cases. Clinical features and laboratory data of the patients with SSc are summarized in Table 2.

At ECG, defects of conduction were detected: 4 patients showed first-degree atrioventricular block, 3 had left anterior fascicular block, and 4 showed right bundle-branch block. At Holter ECG, 3 patients presented > 5000 premature ventricular contractions (PVC), 4 patients > 1000 PVC, and in 4 patients unsustained VT was registered. Moreover, in 2 patients a reduced RR variability was found. The remaining patients showed a great number of ventricular and supraventricular arrhythmias. Echocardiography revealed minimal mitral regurgitation in 6 patients and 1 patient with mild mitral stenosis without regurgitation. Left ventricular dysfunction (ejection fraction 29%)

Table 2. Clinical and laboratory data of patients with systemic sclerosis (SSc).

Patient	Age, yrs, Sex	SSc Form	Autoantibodies	ECG	ECG-Holter	Echocardiographic Abnormalities
1	32 M	dcSSc	Scl-70	RBBB	VT 28s CF 232 c/min	Mild left ventricular hypertrophy/mild MR
2	53 M	dcSSc	ANA, Scl-70	SR, LAFB	No. PVC: 7565 Pairs: 237 (13 runs of ventr. bigeminy)	Segmental hypokinesia of septum and apex; mild MR
3	56 M	dcSSc	ANA, Scl-70	SR, LAFB	No. PVC: 2958 Pairs: 48 18 runs of SVT R on T: 36 100 VT of 4 PVC	TDI negative, dilated left atrium (stenosis LAD 90% treated with PTCA) No abnormalities Mild MR
4	32 F	dcSSc	ANA, Scl-70	SR, RBBB, first-degree AVB	100 VT of 4 PVC	Mild MR
5	75 F	dcSSc	ANA, Scl-70	SR, first-degree AVB	No. PVC: 5000 Pairs: 114 VT: 2 episodes RR variability reduced	Absence of asynchronism (TDI)
6	39 F	lcSSc	ANA	SR, first-degree AVB, RBBB, LAFB	No. PSVC: 65 Pairs: 14 Runs: 2 TSV No. PVC: 1025 Pairs: 1 RR variability markedly reduced	Dilatative biventricular cardiomyopathy intraventricular asynchronism on TDI Mild pericardial effusion
7	53 F	dcSSc	ANA, Scl-70	SR, first-degree AVB	No. PVC: 2302 Pairs: 26 Triplets:1	Diastolic dysfunction with restrictive pattern Diastolic dysfunction
8	29 F	dcSSc	ANA, Scl-70	SR	No. PVC: 1069 Pairs: 13	Mild mitral and tricuspid regurgitation
9	57 F	dcSSc	ANA, Scl-70	Bradycardia Isolated ventr. extrasystole	No. PSVC: 1392 Pairs: 22	Moderate-severe aortic stenosis without regurgitation
10	30 M	dcSSc	ANA, Scl-70	Atrial tachycardia RBBB	No. PVC: 5526 Pairs: 34 Two episodes of ventricular tachycardias	Diffuse hypokinesia stenosis LAD 30–40%

ECG: echocardiogram; dcSSc: diffuse cutaneous SSc; ANA: antinuclear antibodies; CF: cardiac frequency; RBBB: right bundle-branch block; VT: ventricular tachycardia; MR: mitral regurgitation; SVT: supraventricular tachycardia; PVC: premature ventricular contractions; TDI: tissue Doppler imaging; PSVC: premature supraventricular contractions; LAFB: left anterior fascicular block; AVB: atrioventricular block; LAD: left anterior descending coronary artery; PTCA: percutaneous transluminal coronary angioplasty; SR: sinus rhythm.

was observed in 1 patient. Tissue Doppler imaging detected a diastolic dysfunction in 6 patients. In 7 patients, ICD analysis did not show any episodes of shocks and cardiac rhythm was normal during 36 months of followup. In 3 patients, during 36 months of followup, the ICD disclosed episodes of VT, promptly reverted by electrical shock.

**Patient 1.** A 32-year-old patient with dcSSc (first non-Raynaud's symptom in 2000) had lung involvement [decreased DLCO (35%) and chest HRCT indicating interstitial lung disease] treated with monthly pulse cyclophosphamide (1 g/m<sup>2</sup>). Echocardiography was normal but Holter monitoring detected episodes of sustained VT. During one of these, the patient had a syncope in spite of antiarrhythmic therapy with amiodarone. For this reason, an ICD was implanted (St. Jude Medical model Epic DR). In the followup, 2 significant episodes of malignant VT were detected, with a prompt shock discharge and recovery of the sinus rhythm. Moreover, rare episodes of supraventricular arrhythmia were registered. Therefore, therapy with mexiletine was started.

**Patient 2.** A 53-year-old patient with dcSSc (first non-Raynaud's symptom in 1999) had esophageal and muscle involvement and exertion dyspnea. Pulmonary function tests, lung HRCT, and pulmonary artery pressure were normal. Doppler echocardiography showed left ventricular asynergy with normal ejection fraction. Cardiac scintigraphy revealed inducible ischemia of the apex and septum, but coronarography did not demonstrate occlusions of the main coronary arteries. Cardiac Holter monitoring detected 7567 monomorphic PVC with 237 pairs and 13 runs of bigeminy. Amiodarone was withdrawn for hypothyroidism. An ICD (Guidant) was implanted. After 6 months of followup, the ICD showed 4 episodes of malignant VT that were interrupted with DC defibrillator current shock (Figure 1).

**Patient 3.** A 30-year-old patient with dcSSc (antinuclear antibody-positive, Scl-70-positive). Holter monitoring detected 5526 monomorphic PVC with 34 pairs and 1 nonsustained VT. Echocardiography showed diffuse left ventricular hypokinesia and reduced ejection fraction (30%). The patient was not hyperlipidemic. Coronary angiography showed a reduction of 30%–40% of patency lesion of a left coronary artery. Therefore, an ICD was implanted (St. Jude Medical model), and after 6 months, the ICD showed 5 malignant VT episodes interrupted with defibrillator current shock after inefficient acceleration time pulsation (Figures 2 and 3).

## DISCUSSION

The mechanisms underlying ventricular arrhythmias in SSc are complex. Pathologic studies have shown diffuse myocardial fibrosis that provides a substrate for re-entry episodes<sup>13</sup>, but automatic or triggered arrhythmias may also occur. In the literature, only 1 case of SSc with automatic tachycardia, treated with surgical ablation, has been reported<sup>14</sup>. It has been suggested that monomorphic tachycardia in SSc can be sustained by a re-entry mechanism<sup>13</sup>. In SSc, the arrhythmogenic

substrate may result from dynamic vasospasm rather than reduced small coronary perfusion. Indeed, recurrent episodes of coronary spasm in SSc may be reactive to peripheral cold exposure and may be one of the causes of myocardial fibrosis<sup>15</sup>. It could be that patients have both vasospasm and reduced small-vessel perfusion. Unfortunately, this issue remains unresolved. It has been shown that 21% of deaths in patients with SSc were due to SCD<sup>3</sup> and that 12 out of 22 deaths in 183 patients with SSc were due to SCD<sup>5</sup>. In 24% of patients at high risk with both cardiac and skeletal myopathy, sustained VT was documented and 48% died of SCD<sup>16</sup>. In addition to spontaneous VT, the use of antiarrhythmic drugs was predictive of an adverse outcome in this SSc population<sup>16</sup>. A number of diseases other than dilated cardiomyopathy have been associated with an increased incidence of SCD. These include inherited diseases of ion channels, such as long-QT syndrome (LQTS), Brugada syndrome, and catecholaminergic VT. Other structural heart diseases, such as right ventricular dysplasia, hypertrophic cardiomyopathy, and certain types of congenital heart disease, may also be associated with increased risk of SCD. The frequency of these conditions is not as high as that of ischemic or nonischemic dilated cardiomyopathy, so it is difficult to perform randomized controlled trials. Nonrandomized observational studies suggest that high-risk patients may benefit from ICD, and from this it may be inferred that patients with SSc who have VT might also benefit from ICD implantation<sup>17</sup>. One case provides evidence of the clinical usefulness of ICD. In the absence of large-scale trials, there are some disease-specific markers, such as the length of the QT interval in the inherited LQTS, the presence of persistent rather than intermittent right precordial ST elevation in Brugada syndrome, and the degree of left ventricular hypertrophy in patients with hypertrophic cardiomyopathy. These conditions may indicate an increased risk of SCD and make ICD an appropriate choice to prevent it. In SSc, the presence of frequent premature ventricular contractions, such as recurrent couplets, or nonsustained VT, sustained VT with or without symptoms, may represent possible risk factors for SCD.

There is no evidence that drug therapy decreases mortality

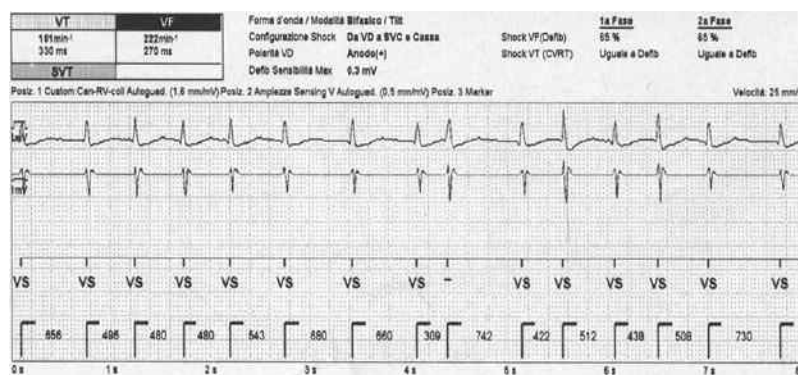


Figure 1. Echocardiogram shows sinus rhythm.

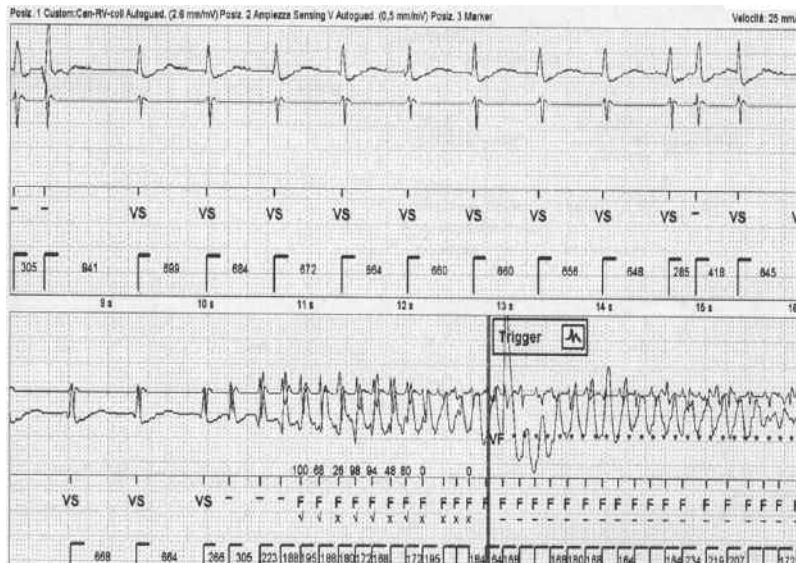


Figure 2. In the Holter echocardiogram, the onset of ventricular tachycardia is visible with inefficient overdrive.

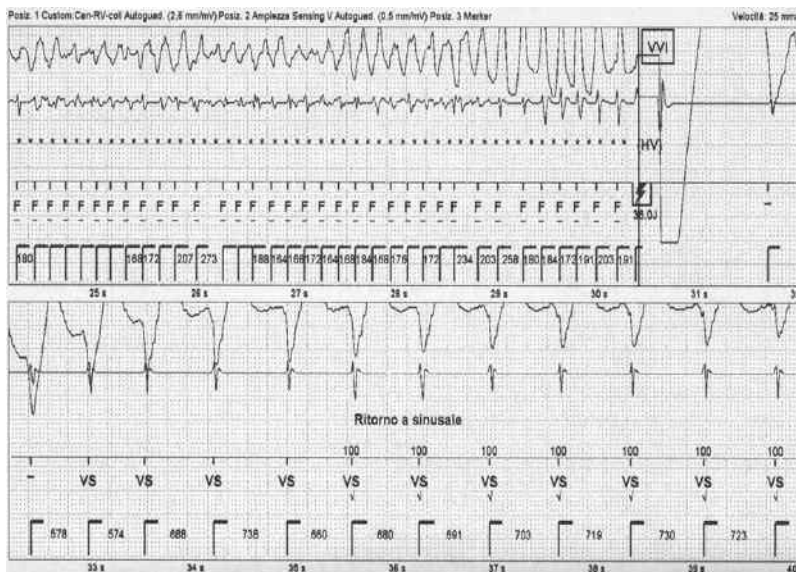


Figure 3. Echocardiogram shows sustained ventricular tachycardia interrupted with DC shock.

in patients with SSc who have VT. The outcome of these patients may even be worse because of the proarrhythmic effect of the antiarrhythmic drug. In other diseases there is evidence that the ICD implant represents an effective therapy for life-threatening ventricular arrhythmias, and that treatment is considered appropriate for patients with complex ventricular arrhythmias. In addition to delivering shocks to stop malignant arrhythmias, the second-generation and third-generation

ICD have a variety of pacing schemes to stop more stable VT.

Our data strongly suggest that ICD implantation should be considered in cases of SSc with malignant ventricular arrhythmias either unresponsive to or with contraindication to drug therapy. It remains to be determined whether patients with SSc who have reduced ejection fraction or dilated cardiomyopathy might also profit from the implantation of a pacemaker-defibrillator.

## REFERENCES

1. Guiducci S, Giacomelli R, Matucci-Cerinic M. Vascular complications of scleroderma. *Autoimmune Rev* 2007;6:520-3.
2. Kahan A, Allanore Y. Primary myocardial involvement in systemic sclerosis. *Rheumatology* 2006;45 Suppl:14-7.
3. Bukley BH, Ridolfi RL, Salyer WR, Hutchins GM. Myocardial lesions of progressive systemic sclerosis. A cause of cardiac dysfunction. *Circulation* 1976;53:483-90.
4. Kostis JB, Seibold JR, Turkevich D, Masi AT, Grau RG, Medsger TA, et al. Prognostic importance of cardiac arrhythmias in systemic sclerosis. *Am J Med* 1988;84:1007-15.
5. James TN. De subitaneis mortibus. VIII. Coronary arteries and conduction system in scleroderma heart disease. *Circulation* 1974;50:844-56.
6. Anvari A, Granger W, Schneder B, Sochor H, Weber H, Schmidinger H. Cardiac involvement in systemic sclerosis. *Arthritis Rheum* 1992;35:1356-61.
7. Perera A, Fertig N, Lucas M, Rodriguez-Reyna TS, Hu P, Steen VD, et al. Clinical subsets, skin thickness progression rate, and serum antibody levels in systemic sclerosis patients with antitopoisomerase I antibody. *Arthritis Rheum* 2007;56:2740-6.
8. Clements PJ, Furst DE, Cabeen W, Tashkin D, Paulus HE, Roberts N. The relationship of arrhythmias and conduction disturbances to other manifestations of cardiopulmonary disease in progressive systemic sclerosis. *Am J Med* 1981;71:38-46.
9. Wranicz J, Zielinska M, Cygankiewicz I, Dzionkowska-Bartkowiak B, Sysa-Jedrzejowska A. Early cardiovascular involvement in patients with systemic sclerosis (SSc). *Med Sci Monit* 2002;8:CR78-82.
10. Martinez-Taboada V, Olalla J, Blanco R, Armona J, Sueiro JF, Rodriguez-Valverde V. Malignant ventricular arrhythmia in systemic sclerosis controlled with an implantable cardioverter defibrillator. *J Rheumatol* 1994;21:2166-7.
11. LeRoy EC, Black C, Fleischmajer R, Jablonska S, Krieg T, Medsger TA Jr, et al. Scleroderma (systemic sclerosis): classification, subsets and pathogenesis. *J Rheumatol* 1988;15:202-5.
12. Pignone A, Scaletti C, Matucci-Cerinic M, Vázquez-Abad D, Meroni PL, Del Papa N, et al. Anti-endothelial cell antibodies in systemic sclerosis: significant association with vascular involvement and alveolo-capillary impairment. *Clin Exp Rheumatol* 1998;16:527-32.
13. Rankin AC, Osswald S, McGovern BA, Ruskin JN, Garan H. Mechanism of sustained monomorphic ventricular tachycardia in systemic sclerosis. *Am J Cardiol* 1999;83:633-6.
14. Gallagher JJ, Anderson RW, Kasell J, Rice JR, Pritchett EL, Gault HJ, et al. Cryoablation of drug-resistant ventricular tachycardia in a patient with a variant of scleroderma. *Circulation* 1978;57:190-7.
15. Long A, Duffy G, Bresnihan B. Reversible myocardial perfusion defects during cold challenge in scleroderma. *Br J Rheumatol* 1986;25:158-61.
16. Follansbee WP, Zerbe TR, Medsger TA Jr. Cardiac and skeletal muscle disease in systemic sclerosis (scleroderma): a high risk association. *Am Heart J* 1993;125:194-203.
17. Passman R, Kadish A. Sudden death prevention with implantable devices. *Circulation* 2007;116:561-71.